

Chapter 10

Computer Assisted Methods for Retinal Image Classification

S. R. Nirmala

Gauhati University, India

Purabi Sharma

Gauhati University, India

ABSTRACT

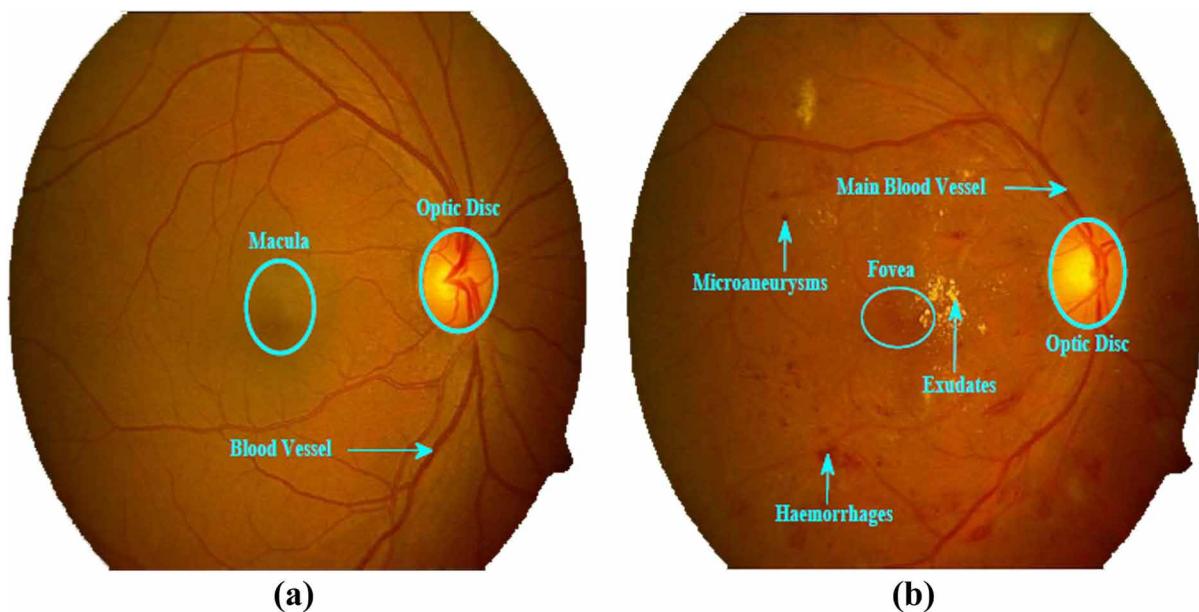
Diabetes maculopathy has become one of the rapidly increasing health threats worldwide. The complication of diabetes associated to retina of the eye is diabetic retinopathy. A patient with the disease has to undergo periodic screening of eye. The ophthalmologists use colour retinal images of a patient acquired from digital fundus camera for disease diagnosis. Limited number of ophthalmology specialists in most of the countries motivates the need for computer based analysis of retinal images using image processing techniques. The results of this process may be used in applications such as, to classify the retinal images into normal and diseased. This could reduce the workload of ophthalmologists, also aid in diagnosis, to make measurements and to look for a change in progression of disease. Some computer based retinal image analysis methods used for the application are briefed in this chapter.

INTRODUCTION

Modern medical imaging offers the potential for major advances in science and medicine as higher fidelity images are produced. It has developed into one of the most important fields within scientific imaging due to the rapid progress in computerized medical image visualization and advances in analysis methods (Dougherty 2011). Computer-aided diagnosis is a vital part of the early detection, diagnosis, and treatment of retinal pathologies. These accomplishments have allowed clinicians to make accurate and efficient diagnoses non-invasively. With medical imaging playing an increasingly prominent role in the diagnosis and treatment of diseases, the challenge is to effectively process and analyze the images in order to extract and interpret useful information about anatomical structures (Dougherty 2011). The number of people with eye diseases is increasing with an increase in the aged population worldwide. So, there is a relative decrease in ophthalmic services, especially in rural areas and developing countries.

DOI: 10.4018/978-1-4666-8493-5.ch010

Figure 1. Digital retinal image (a) Normal retinal image (b) diseased retinal image



The World Health Organization (WHO) has launched “Vision 2020,” a global initiative for the prevention of avoidable visual impairment by the year 2020 (Wild, Roglic, Green, Sicree & King, 2004). The main causes of global blindness are age-related macular degeneration (ARMD), glaucoma, cataract and diabetic retinopathy (DR). If these diseases are detected early and treated, then significant reduction in the progression of eyesight loss is possible.

Retina and Common Retinal Diseases

Retinal imaging and image processing play a crucial role in the care of patients with retinal diseases. Retina is the light sensitive layer at the back of the eye. Digital retinal images are captured by a special modality called fundus camera. Such an image obtained from a local eye hospital (Sri Sankaradeva Nethralaya) is shown in Figure 1. Typical features of normal retinal image include macula, optic disc (OD) and blood vessels as shown in Figure 1 (a). Macula is the dark, central retinal area. The centre of the macula is the fovea. It contains the highest concentration of photosensitive cells and is responsible for sharp central vision and reading vision. The OD is a bright yellowish region in the back of the eye where the optic nerve enters the eye. This also corresponds to the blind spot since there are no photosensitive cells in this location. The blood vessels radiating out from OD supply blood to nourish the inner retinal layers. The ophthalmologists examine the clinically important features in the retinal image for signs of various eye related diseases.

Some of the clinical symptoms of retinal disease are microaneurysms, haemorrhages and exudates as shown in Figure 1 (b). Microaneurysms are small saccular pouches caused by local distension of vessel walls and appear as small red dots. Haemorrhages are the abnormal bleeding of the blood vessels in the retina. Exudates are the fatty material deposited in the retina by leaky blood vessels which appear as bright yellow lesions. The distribution of these pathological signs helps the doctors to evaluate the

22 more pages are available in the full version of this document, which may be purchased using the "Add to Cart" button on the publisher's webpage:

www.igi-global.com/chapter/computer-assisted-methods-for-retinal-image-classification/135888

Related Content

Information and Knowledge Perspectives in Systems Engineering and Management for Innovation and Productivity through Enterprise Resource Planning

Stephen V. Stephenson and Andrew P. Sage (2010). *Emerging Systems Approaches in Information Technologies: Concepts, Theories, and Applications* (pp. 227-256).

www.irma-international.org/chapter/information-knowledge-perspectives-systems-engineering/38183

Performance Evaluation of Different Machine Learning Algorithms Using Credit Scoring Model

Amrit Singh, Harisankar Mahapatra, Anil Kumar Biswal, Milan Samantaray and Debabrata Singh (2023). *The Software Principles of Design for Data Modeling* (pp. 248-260).

www.irma-international.org/chapter/performance-evaluation-of-different-machine-learning-algorithms-using-credit-scoring-model/330500

Practical Application

(2017). *Large-Scale Fuzzy Interconnected Control Systems Design and Analysis* (pp. 195-212).

www.irma-international.org/chapter/practical-application/181992

Use Case Modeling for Industrial Human Resource Management Practices

Suplab Kanti Podder (2023). *The Software Principles of Design for Data Modeling* (pp. 145-154).

www.irma-international.org/chapter/use-case-modeling-for-industrial-human-resource-management-practices/330493

Estimating Interval of the Number of Errors for Embedded Software Development Projects

Kazunori Iwata, Toyoshiro Nakasima, Yoshiyuki Anan and Naohiro Ishii (2014). *International Journal of Software Innovation* (pp. 40-50).

www.irma-international.org/article/estimating-interval-of-the-number-of-errors-for-embedded-software-development-projects/120089