

Chapter 36

Joint Vibration Analysis (JVA)

Ray M. Becker

*International Certifying and Interpretation Instructor of the Total BioPAK System, Private Practice,
USA*

ABSTRACT

This chapter describes Joint Vibration Analysis (JVA) technology that assesses pathological changes that can occur within the Temporomandibular joints. Joint Vibration Analysis (JVA) uses tissue accelerometers to objectively capture vibrations given off by structurally compromised internal TM Joint anatomy. The structural breakdown leads to altered mandibular movement patterns during chewing function. Different attributes of representative JVA vibrations have been shown to indicate the presence of various disease states often seen within the Temporomandibular Joint complex. After being recorded, the JVA software displays the various vibration waveforms for clinician analysis to determine the specific internal derangement present. This chapter provides an overview of the various vibratory waveforms that indicate TM Joint pathology and illustrates the utility of Joint Vibration Analysis as a Temporomandibular Joint diagnostic adjunct.

INTRODUCTION

Temporomandibular Joint (TMJ) Anatomy

The Temporomandibular joint (TMJ) is a ginglymoarthroidial joint, which is also diarthroidal, in that it translates and rotates throughout function. It is comprised of the following components:

- The posterior slope of the eminentia,
- The mandibular condyle,
- The articular disc
- The synovial tissue
- The vascular and innervated retrodiscal tissue, which includes the posterior attachment of the articular disc to both the mandible and to the temporal bone
- The posterior attachment tissue, which is vascular and innervated

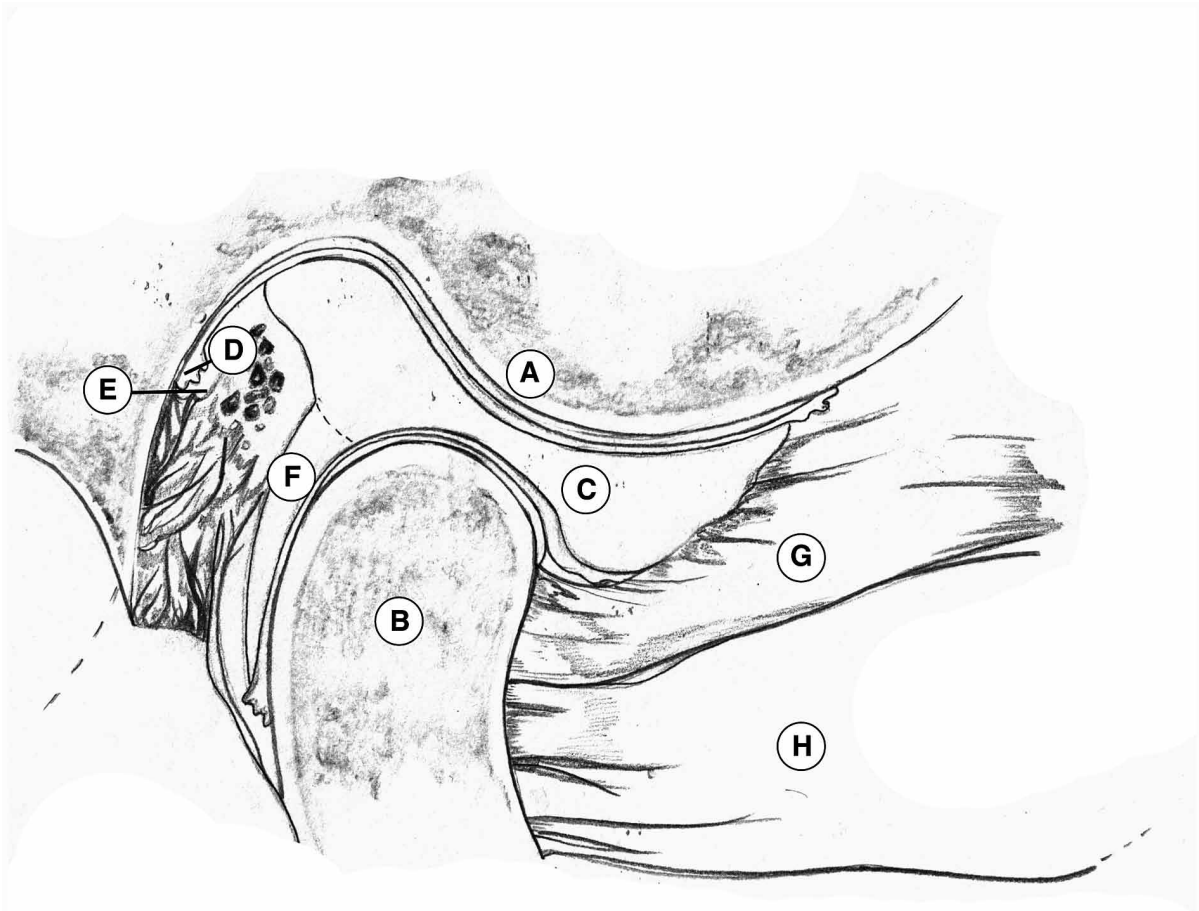
DOI: 10.4018/978-1-5225-0571-6.ch036

Joint Vibration Analysis (JVA)

The articular disc is a biconcave fibro-cartilaginous capsule that normally rests between the head of the mandibular condyle and the articular eminence of the temporal bone. The disc is attached to the lateral and medial poles of the condyle, while also being elastically attached posteriorly to the temporal bone and the mandible. Anteriorly, the disc is attached to a few fibers of the superior belly of the lateral pterygoid muscle, which assists in translating both the disc and the condyle forward upon excursions of the mandible (Figure 1).

Through normal excursive movements of the mandible, the Temporomandibular joint is required to both rotate and translate. A healthy joint will perform this task without giving off any sounds or vibrations throughout its entire range of motion (Ishigaki, Bessette, & Maruyama, 1993).

Figure 1. Lateral cross-sectional view through the right Temporomandibular joint showing: A-posterior slope of eminentia with typical convex contour; B-mandibular condyle; C- biconcave articular disc fitted between a convex eminentia and a convex condylar head; D-synovial tissue; E-retrodiscal tissue including the posterior attachment of articular disc and temporal bone; F-posterior attachment tissue which is innervated and vascular; G-superior belly of lateral pterygoid muscle with fibers attaching to medial aspect of articular disc; H-inferior belly of lateral pterygoid muscle attaching to condyle. (Adapted by Breanna Becker from, Dawson, P.E. (2008). Functional Occlusion: From TMJ to Smile Design, Chapter 5; The Masticatory Musculature., C.V. Mosby, Elsevier. Used with permission.)



54 more pages are available in the full version of this document, which may be purchased using the "Add to Cart" button on the publisher's webpage:

www.igi-global.com/chapter/joint-vibration-analysis-jva/159745

Related Content

Research on Denoising of Brain MRI of Alzheimer's Disease Based on BM3D Algorithm

Xin-lei Chen (2021). *International Journal of Health Systems and Translational Medicine* (pp. 33-43).

www.irma-international.org/article/research-on-denoising-of-brain-mri-of-alzheimers-disease-based-on-bm3d-algorithm/277368

Racially Motivated Police Brutality Is a Community Public Health Issue in the United States

Darrell Norman Burrell, Sharon L. Burton and Grace E. McGrath (2023). *International Journal of Health Systems and Translational Medicine* (pp. 1-15).

www.irma-international.org/article/racially-motivated-police-brutality-is-a-community-public-health-issue-in-the-united-states/315296

Decoding Parkinson's Disease: A Deep Learning Approach to Handwriting Diagnosis

V. R. Azhaguramyaa, K. Srinivasan, S. Oswalt Manoj, M. Rohini and R. Rama Abirami (2024). *Intelligent Technologies and Parkinson's Disease: Prediction and Diagnosis* (pp. 137-163).

www.irma-international.org/chapter/decoding-parkinsons-disease/338821

An Automatic MR Brain Image Segmentation Method Using a Multitask Quadratic Regularized Clustering Algorithm

Lei Hua, Jing Xue and Leyuan Zhou (2021). *International Journal of Health Systems and Translational Medicine* (pp. 44-58).

www.irma-international.org/article/an-automatic-mr-brain-image-segmentation-method-using-a-multitask-quadratic-regularized-clustering-algorithm/277369

Conceptualizing a Real-Time Remote Cardiac Health Monitoring System

Alex Page, Moeen Hassanali, Tolga Soyata, Mehmet K. Aktas, Burak Kantarci and Silvana Andreescu (2017). *Medical Imaging: Concepts, Methodologies, Tools, and Applications* (pp. 160-193).

www.irma-international.org/chapter/conceptualizing-a-real-time-remote-cardiac-health-monitoring-system/159714