

Chapter 6

Histopathological Image Analysis in Medical Decision Making: Classification of Histopathological Images Based on Deep Learning Model

R. Meena Prakash

Sethu Institute of Technology, India

Shantha Selva Kumari R.

Mepco Schlenk Engineering College, India

ABSTRACT

Digital pathology is one of the significant methods in the medicine field to diagnose and treat cancer. The cell morphology and architecture distribution of biopsies are analyzed to diagnose the spread and severity of the disease. Manual analyses are time-consuming and subjected to intra- and inter-observer variability. Digital pathology and computer-aided analysis aids in enormous applications including nuclei detection, segmentation, and classification. The major challenges in nuclei segmentation are high variability in images due to differences in preparation of slides, heterogeneous structure, overlapping clusters, artifacts, and noise. The structure of the proposed chapter is as follows. First, an introduction about digital pathology and significance of digital pathology techniques in cancer diagnosis based on literature survey is given. Then, the method of classification of histopathological images using deep learning for different datasets is proposed with experimental results.

DOI: 10.4018/978-1-5225-6316-7.ch006

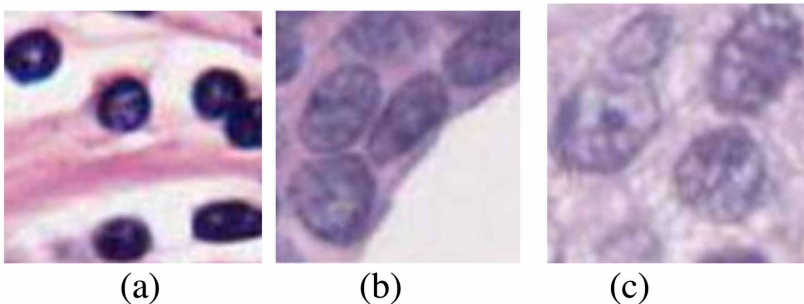
INTRODUCTION

Digital pathology means the investigation of a biopsy or surgical specimen at microscopic level. The tissues are chemically processed and sectioned onto glass slides to study cellular morphology for cancer diagnosis and prognosis. For the tissue components to be visualized under the microscope, the sections are dyed with one or more stains including Hematoxylin-Eosin (H&E) and Immunohistochemical (IHC). The nuclei regions are stained in dark blue colour by Hematoxylin and the other structures like cytoplasm, stroma etc., are stained with pink colour. IHC is used to determine the cancer stage whether it is benign or malignant based on the presence or absence of proteins. After the process of staining, digital images are generated using fast slide scanners which contain one or multiple lenses to magnify the images at X20 or X40 magnification. Uniform light spectrum is used to illuminate the tissue slide. The slide scanners are provided with standard packages for corrections in spectral and spatial illumination variation.

Figure 1 shows the different types of nuclei (Irshad et al, 2014). Lymphocyte is the white blood cell which plays major role in immune system of the body. Epithelial tissues line the outer surfaces of organs, blood vessels and inner surfaces of cavities of human body. Lymphocyte Nuclei have regular shape and are smaller in size than Epithelial nuclei. EN's in high grade cancer tissues are larger in size and have clearly visible nucleoli. Also, they show heterogeneous chromatin distribution and irregular boundaries called nuclear plemorphism.

The problems associated with detection, segmentation and classification of nuclei are due to variation in slides preparation, image acquisition like artifacts caused during image compression, noise etc., and also the overlapping clusters of nuclei. The aspect of nuclei plays a major role in evaluating the existence of cancer and its severity. For example, in breast cancer prediction, the infiltration of LN is related to patient survival and death. Similarly, nuclear plemorphism aids in cancer grading. Mitotic count is an important prognostic parameter in breast cancer grading.

Figure 1. Different types of nuclei (a) LN (b) EN (c) EN in cancer tissue



13 more pages are available in the full version of this document, which may be purchased using the "Add to Cart" button on the publisher's webpage: www.igi-global.com/chapter/histopathological-image-analysis-in-medical-decision-making/212542

Related Content

Employing T-Scan Synchronized with Electromyography to Treat Chronic Occluso-Muscle Disorder

Robert B. Kerstein, DMD (2015). *Handbook of Research on Computerized Occlusal Analysis Technology Applications in Dental Medicine* (pp. 269-356).

www.irma-international.org/chapter/employing-t-scan-synchronized-with-electromyography-to-treat-chronic-occluso-muscle-disorder/122075

Pupil Examination in Children

Iason Mantagos (2022). *The Pediatric Eye Exam Quick Reference Guide: Office and Emergency Room Procedures* (pp. 86-96).

www.irma-international.org/chapter/pupil-examination-in-children/296162

Histopathological Image Analysis in Medical Decision Making: Classification of Histopathological Images Based on Deep Learning Model

R. Meena Prakash and Shantha Selva Kumari R. (2019). *Histopathological Image Analysis in Medical Decision Making* (pp. 139-153).

www.irma-international.org/chapter/histopathological-image-analysis-in-medical-decision-making/212542

Technology Design and Routes for Tool Appropriation in Medical Practices

Manuel Santos-Trigo, Ernesto Suaste and Paola Figuerola (2019). *Advanced Methodologies and Technologies in Medicine and Healthcare* (pp. 252-263).

www.irma-international.org/chapter/technology-design-and-routes-for-tool-appropriation-in-medical-practices/213602

Interactivity in Distance Education and Computer-Aided Learning, With Medical Education Examples

D. John Doyle and Patrick J. Fahy (2019). *Advanced Methodologies and Technologies in Medicine and Healthcare* (pp. 337-350).

www.irma-international.org/chapter/interactivity-in-distance-education-and-computer-aided-learning-with-medical-education-examples/213610