

Chapter 5

Implementation of Deep Learning Neural Network for Retinal Images

R. Murugan

 <https://orcid.org/0000-0002-9341-3810>

National Institute of Technology Silchar, India

ABSTRACT

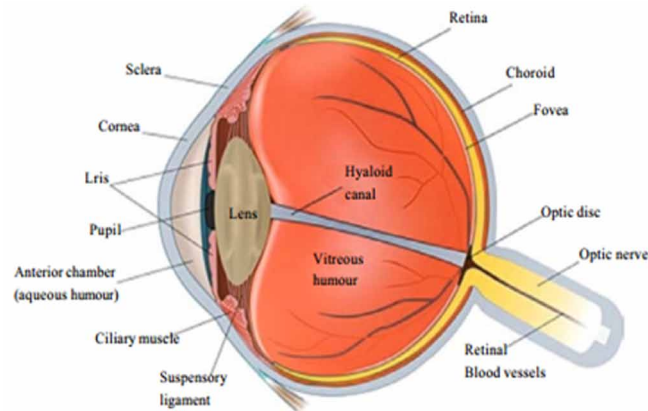
The retinal parts segmentation has been recognized as a key component in both ophthalmological and cardiovascular sickness analysis. The parts of retinal pictures, vessels, optic disc, and macula segmentations, will add to the indicative outcome. In any case, the manual segmentation of retinal parts is tedious and dreary work, and it additionally requires proficient aptitudes. This chapter proposes a supervised method to segment blood vessel utilizing deep learning methods. All the more explicitly, the proposed part has connected the completely convolutional network, which is normally used to perform semantic segmentation undertaking with exchange learning. The convolutional neural system has turned out to be an amazing asset for a few computer vision assignments. As of late, restorative picture investigation bunches over the world are rapidly entering this field and applying convolutional neural systems and other deep learning philosophies to a wide assortment of uses, and uncommon outcomes are rising constantly.

INTRODUCTION

The eye is an important organ that allows human to observe, react and adapt to surrounding environments. It also enables to interpret shapes, colours and dimensions of objects visualized. Eye contains three major layers, an outer layer sclera in continuation with cornea, a vascular layer choroid and the neurosensory component retina. The visible parts of the eye also include the colour (blue, green, brown or a mixture of these) iris, and an opening in the iris, the normally black pupil. A ray of light, after passing through the cornea, which partially focuses the image, passes through the anterior chamber, the pupil, lens, vitreous and is then focused on the retina. The retina is supported by pigment epithelium, which is normally opaque (Livingstone & Hubel, 1988). The Anatomy of human eye is shown in Figure 1.

DOI: 10.4018/978-1-5225-9902-9.ch005

Figure 1. Anatomy of human eye (Source: Livingstone & Hubel 1988)

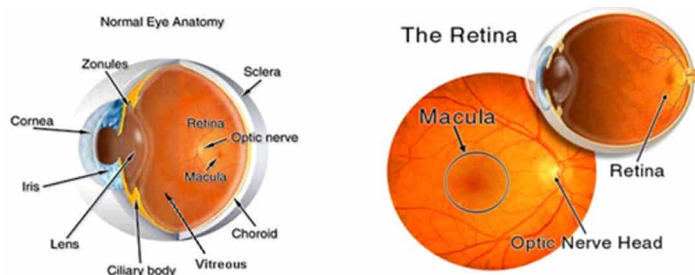


The neurosensory retina, usually called retina, is the largest part of the fundus which is the interior surface of the eye. The retina is a multi-layered sensory tissue that lines the back of the eye. The fundus includes the retina, the optic disc, and the macula. The retina is located in the eyeball as shown in Figure 2. The retina contains millions of photo-receptors that capture light rays and converts them into electrical impulses. These impulses travel along the optic nerve to the brain. The brain then “interprets” the electrical message sent to it, resulting in vision (Foracchia et al. 2004)

There are two types of photo-receptors in the retina: rods and cones, named after their shape. The retina contains approximately 6 to 7 million cones and about 125 million rods. Rods are the photo-receptors that are more responsive to light than the cones. Whether the cones or rods are used, depends on the amount of incoming light. In daylight the cones are the most active, under dark circumstances the rods are the most active and at dusk a combination of the two are used. In the human eye there are three distinct types of cones, and each type of cone responds to a different part of the colour spectrum. When the three different types of cones are located in a small area of the retina, the responses are combined. This enables us to see colors from the color spectrum. The rods, on the other hand, are not sensitive to color (Youssif et al. 2008).

When light enters the pupil, it is focused by the cornea and lens, and is projected onto the retina. The retina converts light into electrical impulses by use of the rods and cones, but the cells that transmit the neural signal to the brain are the ganglion cells. The axons of these ganglion cells make up the optic

Figure 2. Location and appearance of the retina (Source: Foracchia et al. 2004)



17 more pages are available in the full version of this document, which may be purchased using the "Add to Cart" button on the publisher's webpage:

www.igi-global.com/chapter/implementation-of-deep-learning-neural-network-for-retinal-images/234119

Related Content

Automatically Identifying Predictor Variables for Stock Return Prediction

Da Shi, Shaohua Tan and Shuzhi Sam Ge (2009). *Artificial Higher Order Neural Networks for Economics and Business* (pp. 60-78).

www.irma-international.org/chapter/automatically-identifying-predictor-variables-stock/5277

Fundamentals of Graph for Graph Neural Network

Vinod Kumar, Himanshu Prajapati and Sasikala Ponnusamy (2023). *Concepts and Techniques of Graph Neural Networks* (pp. 1-18).

www.irma-international.org/chapter/fundamentals-of-graph-for-graph-neural-network/323818

Artificial Neural Networks (ANNs) and Solution of Civil Engineering Problems: ANNs and Prediction Applications

Melda Yucel, Sinan Melih Nigdeli and Gebrail Bekda (2020). *Artificial Intelligence and Machine Learning Applications in Civil, Mechanical, and Industrial Engineering* (pp. 13-38).

www.irma-international.org/chapter/artificial-neural-networks-anns-and-solution-of-civil-engineering-problems/238137

Prediction of High-Risk Factors in Surgical Operations Using Machine Learning Techniques

Anitha N. and Devi Priya R. (2020). *Handbook of Research on Applications and Implementations of Machine Learning Techniques* (pp. 201-221).

www.irma-international.org/chapter/prediction-of-high-risk-factors-in-surgical-operations-using-machine-learning-techniques/234125

Bipolar Neutrosophic Cubic Graphs and Its Applications

C. Antony Crispin Sweetey, K. Vaiyomathi and F. Nirmala Irudayam (2020). *Handbook of Research on Advanced Applications of Graph Theory in Modern Society* (pp. 492-536).

www.irma-international.org/chapter/bipolar-neutrosophic-cubic-graphs-and-its-applications/235550